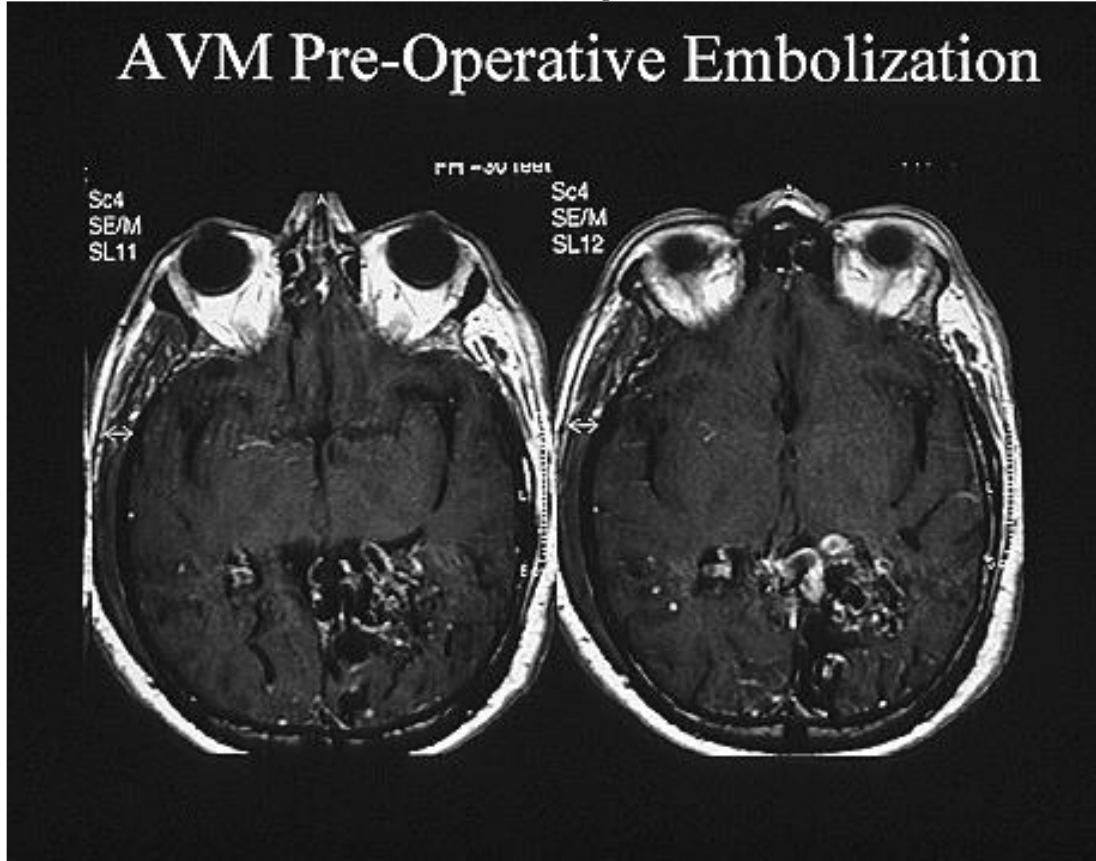


TREATMENT OF INTRACRANIAL ARTERIOVENOUS MALFORMATIONS

Case Report:

A 45 year old man presented with headache and right visual field loss (homonymous hemianopia). MR imaging (Figure 1) followed by angiography (Figure 2) demonstrated a left occipital arteriovenous malformation (AVM). The patient opted for AVM treatment using endovascular embolization. Post angiographic studies showed no residual AVM. Follow up studies failed to demonstrate AVM recurrence over the next 5 years.

FIGURE 1: Brain MRI demonstrates a left occipital AVM



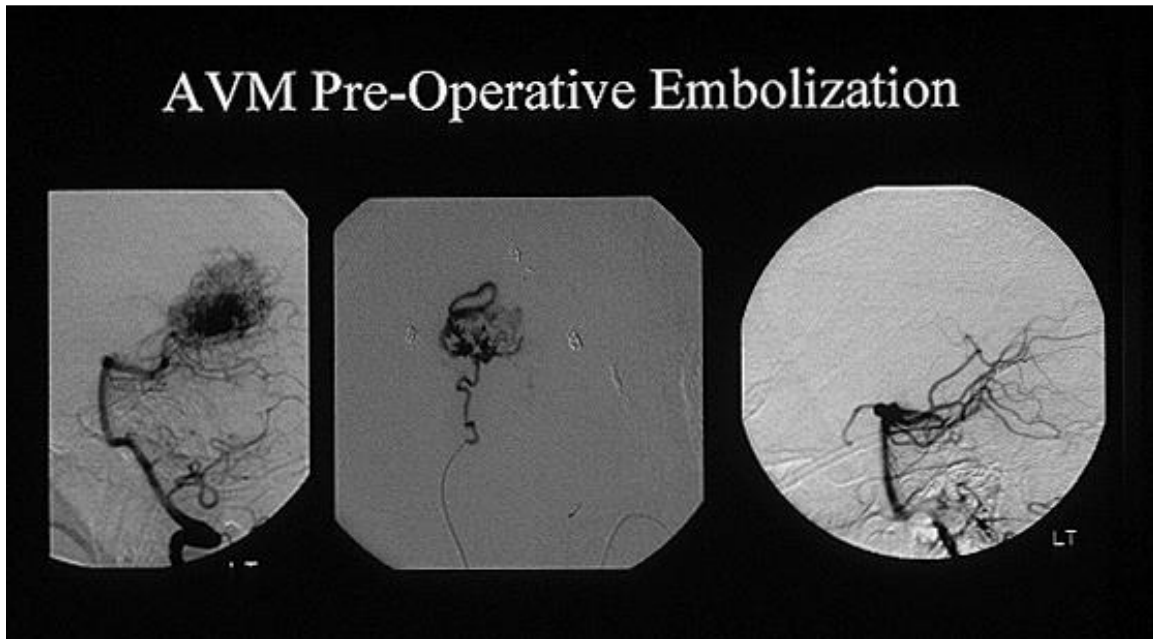


FIGURE 2: The left sided image shows the left occipital AVM. The center image shows a microcatheter angiogram of the AVM. The right sided image shows no residual blood flow to the AVM after endovascular embolization.

Vascular Malformation Categories:

The five types of intracranial vascular malformations include arteriovenous malformations (AVM), venous angiomas, angiographically occult malformations, cavernous malformation, arteriovenous fistula, and capillary telangiectasia. This newsletter will discuss the management of AVMs.

AVM Etiology:

Brain AVMs are congenital abnormalities that harbor direct connections between arteries and veins without a normal capillary bed between the two. These abnormalities are thought to develop during weeks 4-8 of life and occur because the endothelial network of embryologic vessels that normally develop into the capillary bed, fails to normally differentiate.

Incidence, Prevalence and Demographics:

The incidence of AVMs is 1/100,000 while the prevalence in the United States is 0.1%. As MRI imaging becomes more common, these numbers may rise. Familial and sexual associations have not been identified.

Clinical Presentation:

AVMs may remain asymptomatic. When symptoms develop they can include intracranial hemorrhage with associated brain injury and perhaps death, headache, focal or generalized seizures, and/or progressive neurologic decline in function secondary to vascular steal phenomenon. The latter is due to blood flow being diverted through the low resistance AVM vascular network and away from normal brain thus leading to a hypoperfusion condition in the normal brain tissue. The risk of hemorrhage is 2-4% per year. Risk of death from AVM is 1%/year. Finnish studies have shown that when simply followed, 70% of AVMs present with hemorrhage while 24% present with seizures. 25% of patient deaths were due to AVM hemorrhage and the mean age of death was 44 years compared to 77 years in individuals without an AVM. Morbidity and mortality was 2.7%/year and 1%/year, respectively (J Neurosurg. 73:387-391, 1990; Acta Neurochir. 22:125-128, 1970).

Assessment:

Treatment of AVMs depends upon a patient's age, co-morbidities, clinical symptoms, AVM size, location, anatomy, and patient preference. Age at the time of detection is of critical importance since as estimated lifespan decreases, the benefits of treatment also decrease since the cumulative risk of yearly rupture decreases. For example, assuming a bleed rate of 3% per year a 45 year old patient has on average a 64% life time risk of hemorrhage while a 75 year old patient has on average a 28% risk of life time hemorrhage. When age and co-morbidities make treatment an option the first step in evaluating an AVM for treatment involves imaging using MRI and catheter angiography. These two modalities will help the clinician determine size, location within the brain as it relates to critical structures, and AVM structural anatomy. Such determinations can estimate the risks of surgical treatment. These risks can be compared to the risk of hemorrhage and a risk/benefit ratio can be determined.

Once MRI and catheter angiography are completed, the most common method used to categorize an AVM is to calculate a Spetzler-Martin Score. This system takes into consideration an AVMs diameter (<3cm 1 point; 3-6 cm 2 points; >6cm 3 points), location (in eloquent brain, 1 point; in non-eloquent brain, 0 points), and pattern of venous drainage (superficial venous drainage, 0 points; deep venous drainage, 1 point). For example, a 2 cm AVM located in the right anterior frontal lobe with superficial venous drainage would be given a Spetzler-Martin Score of 1). Spetzler-Martin scores correlate with expected outcomes after surgery. Score (Grade) 1 AVMs have almost no risk for post-surgical deficits, Score2 (Grade) AVMs have a 5%

risk of minor post surgical deficit, Score 3 (Grade) AVMs have a 12% risk of post surgical minor deficit and 4% risk of post surgical major deficit, Score 4 (Grade) AVMs have a 20% risk of post surgical minor deficits and 7% risk of post surgical major deficits, and Score 5 (Grade) AVMs have a 19% risk of post surgical minor deficits and a 12% risk of post surgical major deficits.

Treatment of Unruptured AVM:

If a patient based on age, comorbidities, signs and symptoms, and preference is deemed a candidate for treatment three options exist.

Radiosurgery: Treatment of an AVM using minimally invasive stereotactic radiosurgery can be effective for AVMs that measure ≤ 3 cm in diameter. This modality causes endothelial proliferation, thickening of the vessel wall and vessel occlusion over a 1-2 year period after treatment. Depending upon AVM size, obliteration rates 2 years after treatment can approach 80%. Cure rates with two radiosurgery treatments 2-3 years apart can be greater than 80%. Risks of radiosurgery can include radiation necrosis to normal brain. This risk is less than 5%.

Endovascular Therapy: Some AVMs can be completely eliminated by advancing a catheter from the femoral artery in the groin into the vessels of the brain that supply blood to the lesion (aka: feeding vessel). Embolic agents (glue, platinum coils, polyvinyl alcohol particles) can then be injected into the AVM to cut off its blood supply. If all blood supply can be eliminated the AVM may be cured. Close imaging follow-up studies are necessary to assure that the AVM does not recur over time. In some situations, endovascular embolization can be used to reduce the size of an AVM to make it small enough to be treated with radiosurgery. In most situations, embolization is used to reduce the blood supply to an AVM prior to surgical resection. Risks of embolization (morbidity/mortality) are generally less than 10% depending upon the vessels being treated and the location of the AVM in the brain.

Open Surgical Resection: For AVMs larger than 3 cm in diameter, surgical resection is generally recommended in patient's whose signs and symptoms warrant such therapy. As stated above, the risks of surgery can be estimated using the Spetzler-Martin Scoring System. By comparing the natural history over time of an unruptured lesion to the risks of surgery using the Spetzler-Martin System a surgeon and patient can decide if resection is a reasonable course of action.

Treatment of Ruptured AVM:

Treatment of a ruptured AVM is complex in terms of patient selection, surgical timing, and surgical approach. Such discussion is beyond the scope of this review. Suffice to say, the majority of ruptured AVMs undergo surgical resection in a delayed fashion using surgery alone or embolization and surgical resection in combination.

Treatment of AVMs With Associated Aneurysms:

Some AVMs have associated aneurysms which are felt to develop on vessels that supply the AVM due to higher than normal blood flow through the involved arteries. Treatment of these aneurysms depends upon their location. Aneurysms that are located close to the AVM will often disappear over time once the AVM is eliminated and flow through the vessels returns to normal. Aneurysms that are located within the AVM are obliterated when the AVM is eliminated. Aneurysms located at arterial locations distant from the AVM require treatment using surgical clipping or endovascular coiling.