

MULTIDISCIPLINARY APPROACH TO TRAUMATIC INTRACRANIAL ANEURYSMS SECONDARY TO SHOTGUN AND HANDGUN WOUNDS

Michael B. Horowitz, M.D., Thomas A. Kopitnik, M.D., Fraser Landreneau, M.D., Dharamdas M. Ramnani, M.D., Elisabeth J. Rushing, M.D., Eugene George, M.D., Phillip P. Purdy, and Duke S. Samson, M.D.

Department of Neurosurgery, University of Texas Southwestern Medical Center at Dallas, Dallas, Texas

Horowitz MB, Kopitnik TA, Landreneau F, Ramnani DM, Rushing EJ, George E, Purdy PP, Samson DS. Multidisciplinary approach to traumatic intracranial aneurysms secondary to shotgun and handgun wounds. *Surg Neurol* 1999;51:31-42.

BACKGROUND

Traumatic intracranial aneurysms (TICAs) may develop following gunshot injuries to the head. Management of these lesions often combines various aspects of micro-neurosurgical and endovascular techniques to safely repair or obliterate vessel defects.

METHODS

We reviewed our experience over the last 18 years and identified five cases of intracranial aneurysms following gunshot and handgun wounds that were treated surgically and/or endovascularly.

RESULTS

All patients had successful obliteration of their lesions using a variety of therapeutic modalities aimed at preserving neurologic function while at the same time eliminating the aneurysm from the circulation.

CONCLUSION

Both microneurosurgery and endovascular surgery have important roles to play in the management of TICAs. In some cases, both methods can be combined to eliminate lesions and maximize patient recovery in a safe, efficient, and effective fashion. © 1999 by Elsevier Science Inc.

KEY WORDS

Aneurysm, traumatic, shotgun, coils, bypass.

Traumatic intracranial aneurysms (TICAs) secondary to missile injuries are rare occurrences. The majority of these lesions develop in the anterior and middle cerebral artery distributions.

We report five cases over an 18-year period. All were secondary to shotgun and handgun blasts with involvement of the cavernous carotid, middle cerebral, and posterior cerebral arteries. Review of the available literature reveals only 44 previously reported TICAs. None of these were located along the posterior cerebral artery and none were managed with excision and bypass. Only one other case was treated using superficial temporal artery-middle cerebral artery bypass. This paper will report our management of five cases using a variety of arterial bypass and trapping procedures. Pertinent literature is reviewed.

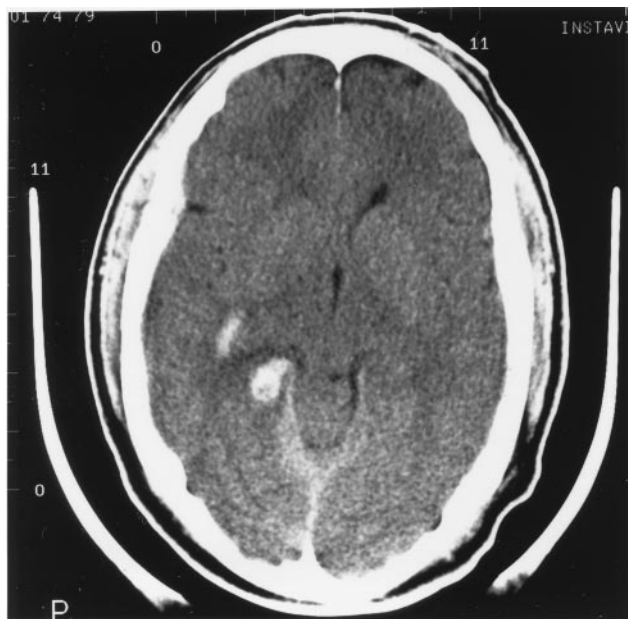
CASE REPORTS

CASE 1

HISTORY A 35-year-old left-handed man presented with a shotgun blast to the head. The projectiles traveled from right to left across the patient's face. His right eye was enucleated, and several metal fragments entered the head through the left orbit. A computed tomography (CT) head scan demonstrated intraparenchymal and intraventricular hemorrhage along with a subdural hematoma (Figure 1). A cerebral arteriogram revealed a 2- to 3-mm non-branch point aneurysm involving the right posterior cerebral artery (PCA) along the P2 segment (Figure 2). The decision was made to repeat the arteriogram 1 week later to see whether the aneurysm resolved, remained the same, or enlarged. Because the patient had already lost the use of his left eye, we were cautious about prematurely performing any procedure that might infarct his right

Address reprint requests to: Dr. Michael B. Horowitz, Department of Neurosurgery, University of Texas Southwestern Medical Center at Dallas, 5323 Harry Hines Blvd, Dallas, TX 75235-8855.

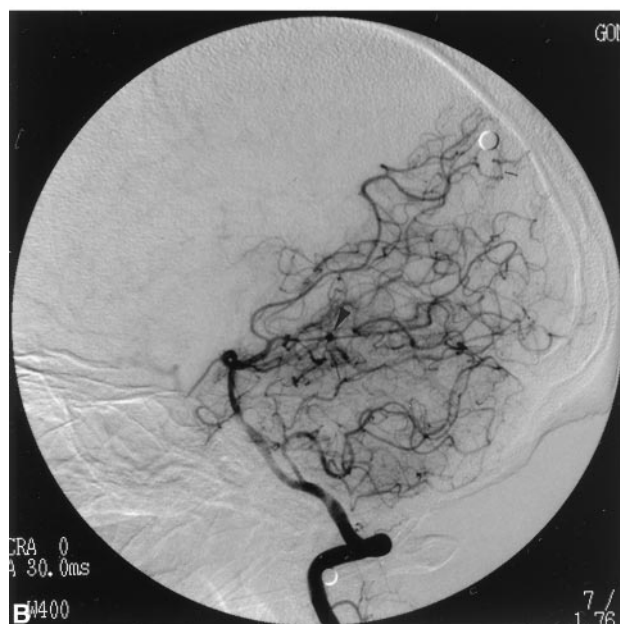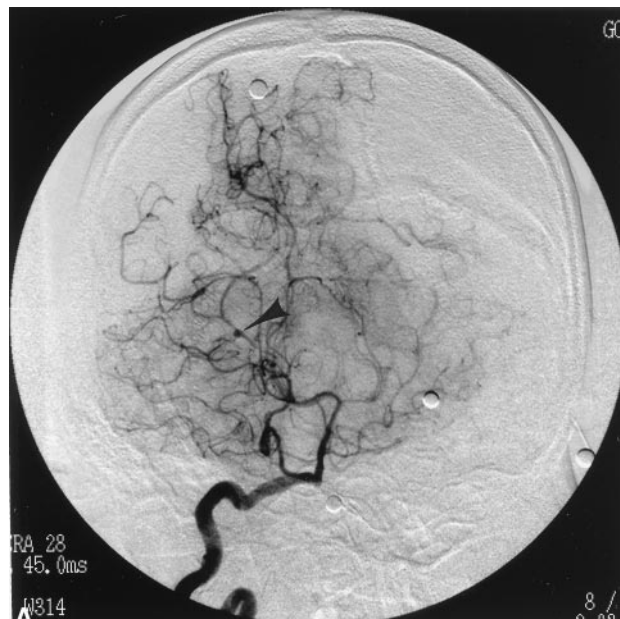
Received June 12, 1997; accepted September 23, 1997.



1 Non-contrast head CT demonstrating subarachnoid and intraparenchymal hemorrhage.

calcarine cortex and further compromise his remaining vision. One week later, the arteriogram was repeated demonstrating enlargement of the aneurysm (Figure 3). This change made it imperative to obliterate the lesion for fear that it would rupture.

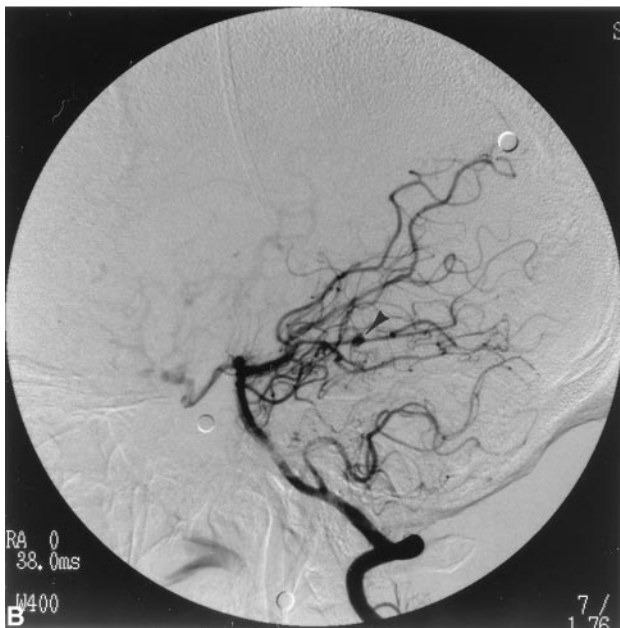
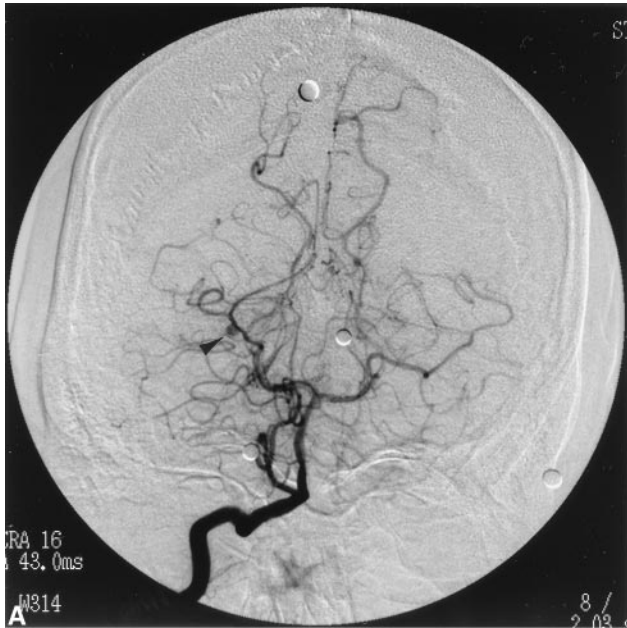
SURGICAL PROCEDURE A right coronal ventriculostomy was inserted to help provide brain relaxation later in the case. The patient was then placed into the lateral decubitus position with his right side up. A cutaneous flap was elevated and a 6-cm segment of superficial temporal artery was harvested, flushed, and soaked in heparinized saline to be used later for interposition grafting should aneurysm resection become necessary. A temporal craniotomy was then performed. The temporal bone was aggressively drilled until it was flat with the floor of the middle fossa and petrous bone. The dura was opened and a chronic subdural hematoma capsule was resected. The ventriculostomy was opened and cerebrospinal fluid was evacuated. By elevating the temporal lobe, the incisura and ambient cistern arachnoid could be identified. The arachnoid was opened, and cranial nerve 3 and the basilar apex were visualized. The PCA was traced caudally along the P1 and P2 segments until a gliotic area with adhesions between brain and tentorium was identified. This region presumably harbored the aneurysm. Sharp dissection along the PCA distal to the adherent region provided distal control of the vessel. Sharp dissection and resection of brain permitted visualization of the aneurysm, a 5-mm,



2 AP (A) and lateral (B) right vertebral artery arteriogram demonstrating a PCA aneurysm (arrowhead).

asymmetric, fusiform dilatation of the PCA. A right-angled Yasargil clip was placed across the aneurysm dome, but this only served to occlude the distal PCA without completely obliterating the aneurysm.

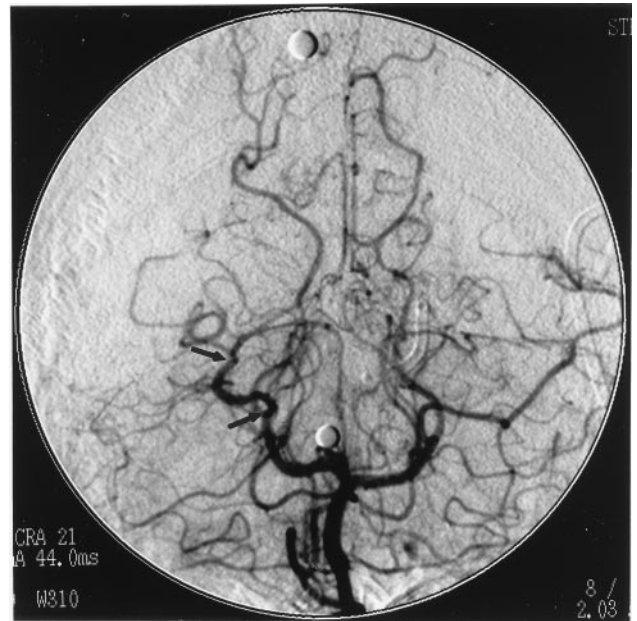
After inducing etomidate burst suppression, temporary clips were placed across the PCA proximal and distal to the aneurysm. The aneurysmal segment of vessel was resected and the superficial temporal artery (STA) graft was inserted as an interposition graft with two end-to-end anastomoses



3 AP (A) and lateral (B) right vertebral artery arteriogram demonstrating PCA aneurysm interval enlargement (arrowhead).

using 10-0 nylon suture. The patient was not heparinized. After completing the anastomoses, the temporary clips were removed. The graft was noted to be pulsatile and patent. A microdoppler ultrasound probe demonstrated excellent signal both distally and proximally.

The patient awoke without deficit. Vision remained normal. A repeat arteriogram the following day demonstrated a patent graft with excellent distal runoff (Figure 4). Follow-up CT revealed no infarcts.

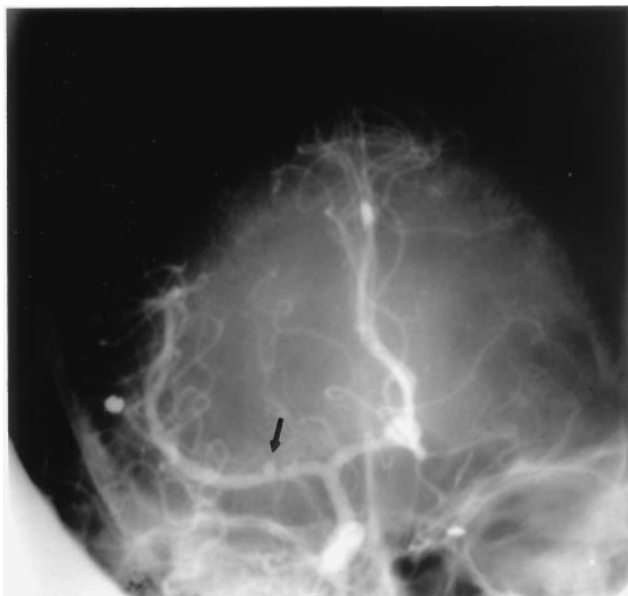


4 Vertebral arteriogram demonstrating interposition graft at site of previous PCA aneurysm (segment located between arrowheads).

CASE 2

HISTORY A 17-year-old man presented with a shotgun blast to the head with one pellet entering the head through the right orbit. A head CT demonstrated a right subdural hematoma with mass effect and subarachnoid hemorrhage. The subdural hematoma was evacuated. The following day, a cerebral arteriogram revealed a small, presumably post-traumatic M1-segment middle cerebral artery (MCA) aneurysm (Figure 5). The patient remained neurologically normal. One week later, the arteriogram was repeated. This study demonstrated significant aneurysm enlargement (Figure 6). Surgery was recommended in order to eliminate the lesion prior to rupture.

SURGICAL PROCEDURE A right frontotemporal craniotomy was performed followed by a right STA-MCA bypass. The proximal Sylvian fissure was then opened, and proximal and distal MCA control was obtained. After 80 minutes of proximal and distal occlusion, the aneurysm was clip reconstructed. Postoperatively, the patient remained unchanged. A repeat arteriogram several days following surgery demonstrated marked supraclinoid internal carotid artery vasospasm, no significant antegrade MCA filling past the clip, and excellent retrograde MCA opacification from the bypass graft (Figure 7). A final arteriogram performed several weeks following surgery revealed a normal MCA, no residual



5 Right internal carotid artery arteriogram demonstrating right MCA aneurysm (arrow).

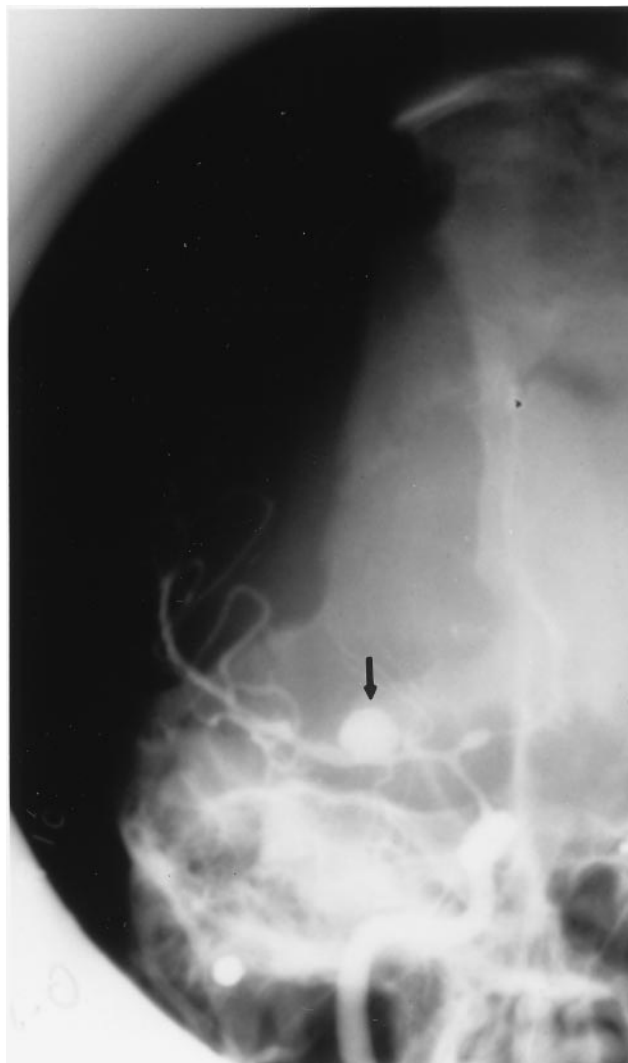aneurysm, and an occluded graft. The patient remained neurologically normal.

CASE 3

HISTORY AND SURGICAL PROCEDURE A 25-year-old man presented following a shotgun wound to the face. A cerebral arteriogram revealed contrast extravasation from a cavernous carotid traumatic aneurysm into the sphenoid sinus and retropharynx (Figure 8). Upon inflation of a balloon in the internal carotid artery (ICA) the patient immediately became hemiplegic. The balloon was deflated and he was immediately brought to the operating room where a saphenous vein bypass graft was sewn from the external carotid artery to the MCA (Figure 9). The ICA was then sacrificed just distal to its origin in the neck and below the ophthalmic artery in the head. Postoperatively, the patient remained neurologically normal.

CASE 4

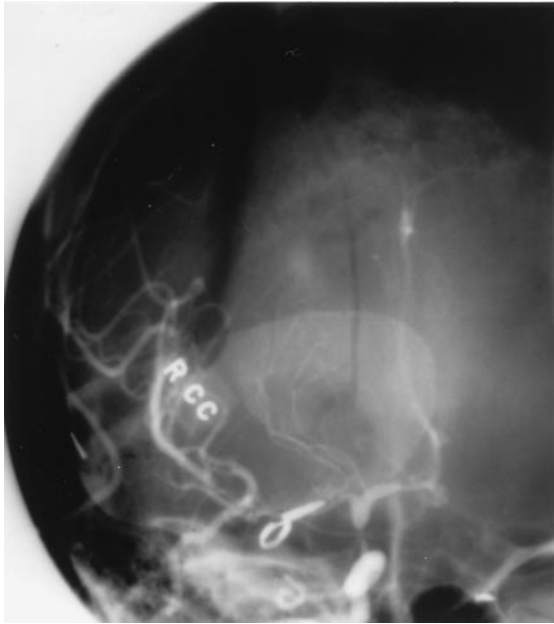
HISTORY AND SURGICAL PROCEDURE A 27-year-old male victim of a drive-by shooting with a handgun was admitted to the emergency room with bilateral traumatic orbital disruptions from a bullet that crossed the anterior and middle fossae from right to left. The patient's best neurologic examination consisted of following commands with his right side. His left side was profoundly hemiparetic. A CT scan (Figure 10) and an arteriogram were then performed to search for vascular injuries. The latter study revealed a small false aneurysm involving a left orbitofrontal artery branch and some irregular-



6 Right internal carotid artery arteriogram demonstrating interval enlargement of right MCA trunk aneurysm.

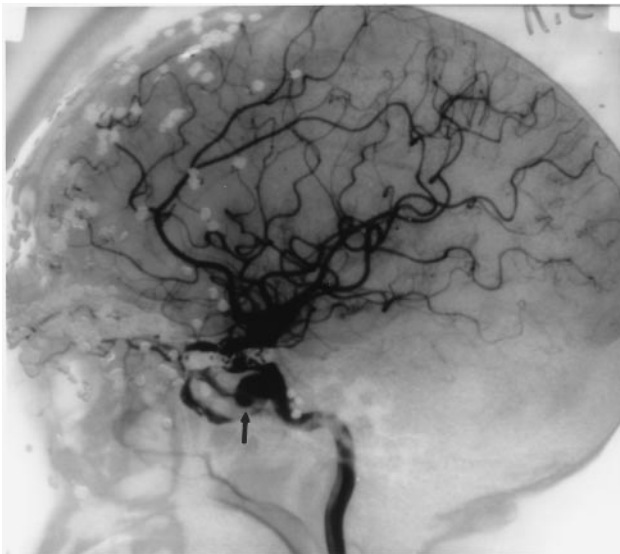
ity along the posterior wall of the right supraclinoid carotid artery (Figure 11). The patient was transferred to the intensive care unit and observed. One week later, he underwent repair of his anterior fossa floor defect. The following day, he experienced a worsening of his neurologic examination, and a CT scan demonstrated pancisternal subarachnoid hemorrhage. A repeat cerebral arteriogram revealed absence of the orbitofrontal false aneurysm and the presence of a large right supraclinoid carotid aneurysm in the region of the previously mentioned irregularity (Figure 12). The decision was made to investigate the possibility of vessel sacrifice.

Because of the patient's condition, his neurologic examination was not reliable. A 45-minute temporary balloon occlusion of the ICA was conducted



7 Right common carotid artery arteriogram demonstrating aneurysm obliteration and MCA filling via bypass graft.

using continuous EEG monitoring. The EEG did not change throughout the study. While the balloon was inflated, 30 mCi of Te-99 and Biscisate dihydrochloride (Neurolite, Dupont-Merck, Billerica, MA) was administered intravenously, so that single photon emission CT (SPECT) images could be obtained. At the end of the balloon occlusion test, we feared that balloon deflation and the subsequent sudden



8 Right internal carotid artery arteriogram demonstrating a cavernous carotid aneurysm (arrow) with active contrast extravasation.

inflow of arterialized blood into the aneurysm of a heparinized patient would lead to aneurysm rupture. Therefore, the systolic blood pressure was reduced to 90 mm Hg, and the balloon was deflated gradually over 30 seconds. The subsequent SPECT images demonstrated low flow in regions of the right hemisphere that were already hypodense on CT, thus leading us to surmise that these were areas of fixed deficits secondary to the gunshot wound.

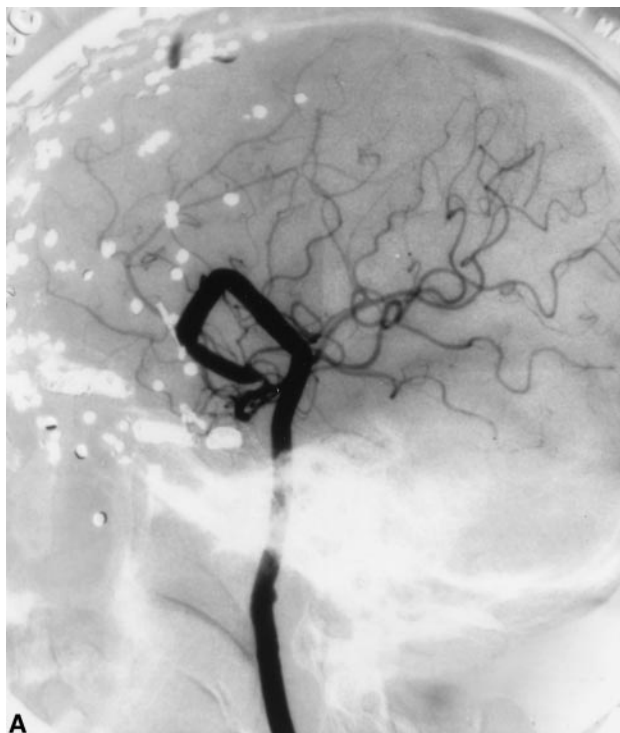The patient was returned to the angiography suite. A temporary balloon catheter was then advanced back into the ICA, and the balloon was inflated to induce flow arrest. A microcatheter was then advanced coaxially to the level of the ophthalmic artery, and the ICA was sacrificed using a variety of Guglielmi detachable coils and Gianturco coils. The balloon was then deflated, and no antero-graduate flow was present. The patient continued to fill the right MCA from the left ICA injection, which did not show retrograde opacification of the aneurysm. The following day, the patient was taken to the operating room where the ICA was clipped proximal to the posterior communicating artery, thus trapping the diseased segment.

Postoperatively, the patient was stable with no worsening of his neurologic examination until 5 days later when he began to decerebrate. Repeat angiography revealed severe vertebral, basilar, left ICA, and left MCA vasospasm. Angioplasty of each of these vessels was successfully completed, although the patient failed to improve. A final left ICA arteriogram following angioplasty demonstrated coil and clip position and collateral filling of the right middle cerebral artery (Figure 13).

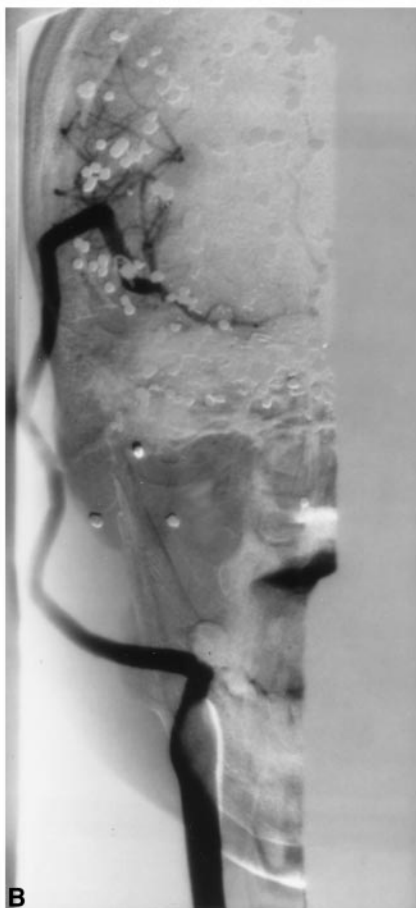
CASE 5

HISTORY AND PROCEDURES A 33-year old man was shot near the right mastoid with a handgun by his wife. Admission GCS was 15. Multiple bone fragments protruded through the scalp. A head CT revealed a right posterior temporal/occipital hematoma and contusion with right-to-left shift (Figure 14). The patient was intubated, an intracranial pressure monitor was inserted, and he was transferred to the angiography suite to determine the presence of any false aneurysms as well as a transverse/sigmoid sinus injury. While on the table, the patient's right pupil dilated. A right common carotid injection was quickly performed, which was normal, and he was taken directly to the operating room where a partial temporal and occipital lobectomy were performed.

Postoperatively the patient was following commands bilaterally. One week following admission, his arteriogram was repeated. This study demon-

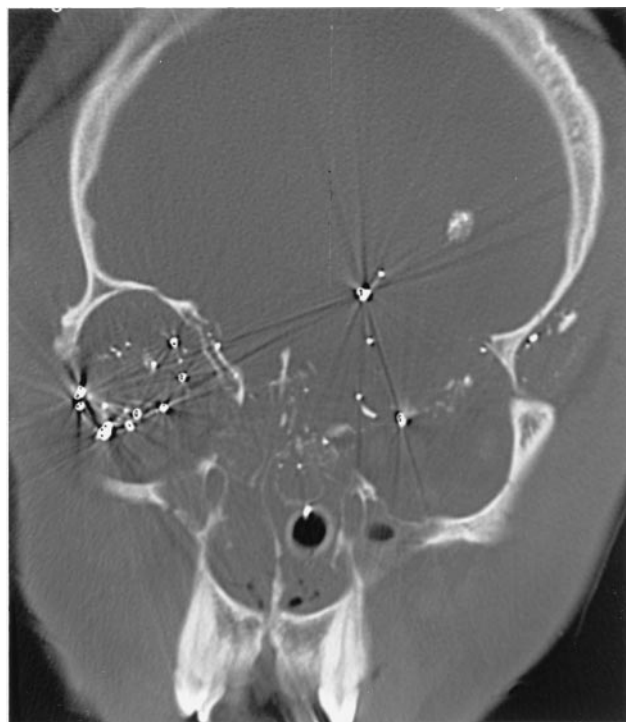


A



B

9 Lateral (A) and AP (B) arteriograms following ICA occlusion, aneurysm trapping, and external carotid to MCA vein bypass.



10 Head CT demonstrating intracranial shotgun pellets.

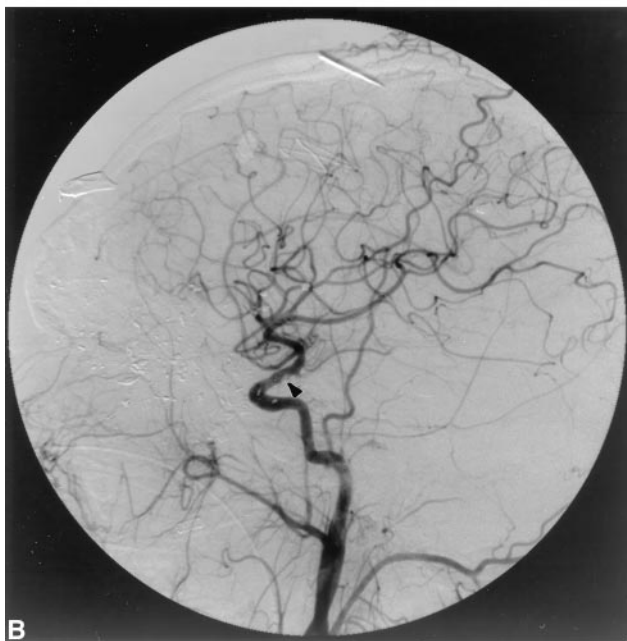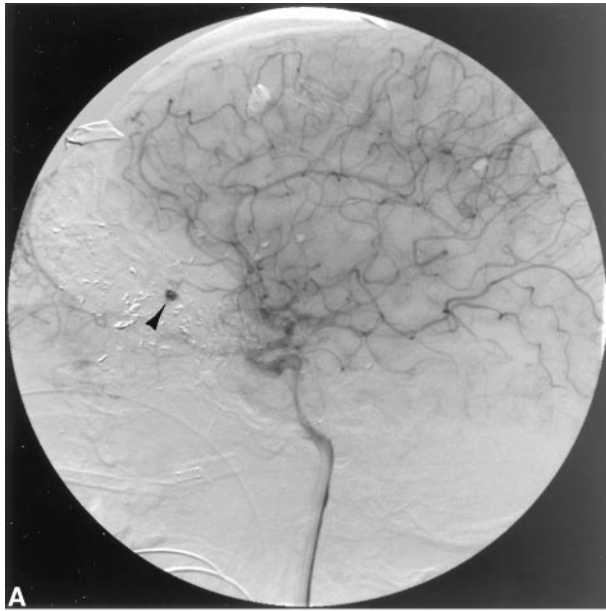
strated a distal right parieto-occipital PCA branch false aneurysm (Figure 15). This lesion was treated by selectively catheterizing the feeding artery and sacrificing it just proximal to the aneurysm, using seven 5-mm and 2-mm coils (Figure 16). Following the procedure, the aneurysm no longer opacified, and the patient's examination remained unchanged.

HISTOLOGY

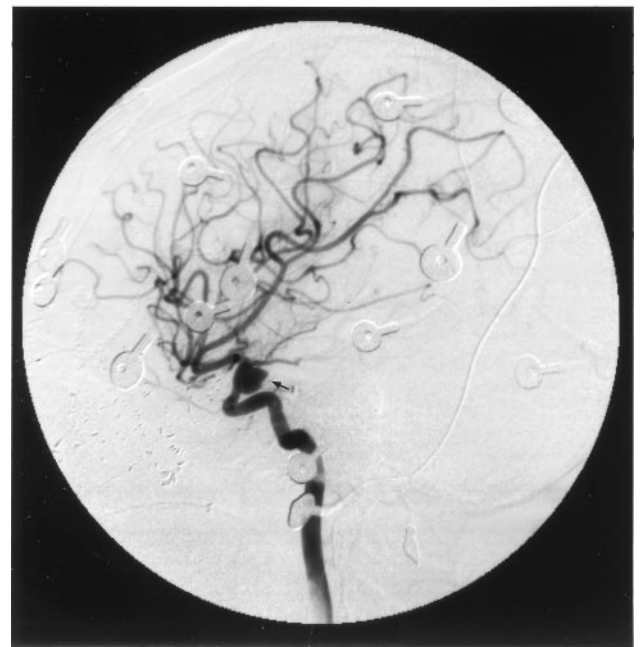
The resected aneurysm from Case 1 was sectioned and analyzed with H&E staining. The microscopic evaluation demonstrated fragmented intima, fresh hemorrhage, and granulation tissue. Myofibroblasts, inflammatory cells, and macrophages were found around the area of vessel disruption (Figure 17).

DISCUSSION

Most information regarding TICAs secondary to missile injuries comes from recent conflicts in Iran and Lebanon [1,6]. TICAs following missile injuries are rare occurrences. Aarabi [1] identified 8 anterior circulation aneurysms in 225 consecutive patients undergoing cerebral angiography following missile injuries to the head (3% incidence). Hadd-



11 Left internal carotid artery arteriogram (A) demonstrating a traumatic orbitofrontal artery aneurysm (arrowhead). Right internal carotid artery arteriogram (B) demonstrates irregularity along the posterior carotid wall.



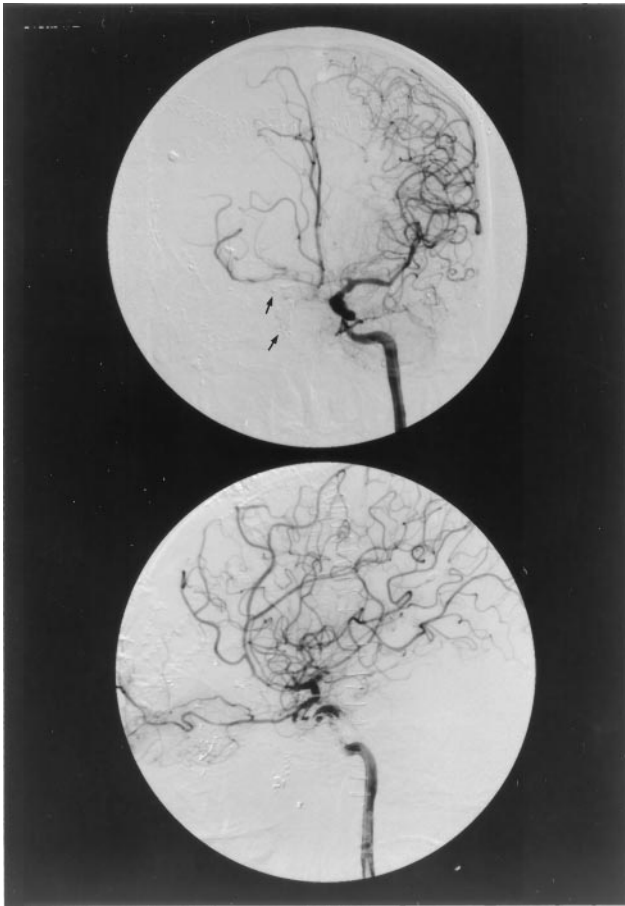
12 Right internal carotid artery arteriogram demonstrating development of a posterior carotid wall aneurysm (arrow) at the site of the previously visualized vessel wall irregularity.

ad's [6] review in 1991 revealed 30 previously reported patients [1-11,13-20]. Nineteen of these were secondary to gunshot wounds, and the remainder were due to shrapnel injuries. Only two lesions were located along posterior circulation vessels, one involving the basilar and the other involving the superior cerebellar artery. The author added 14 additional cases from the Lebanese con-

flict, bringing the total number of reported cases to 44 [6]. Thirteen of these cases were secondary to shrapnel injuries, and all were located along anterior circulation vessels. All cases were either observed, treated with proximal vessel sacrifice, or managed using primary aneurysm clipping or wrapping. No cases of PCA TICAs were reported, no cases were managed using aneurysm excision and interposition grafting, and only one case was managed using a bypass [20].

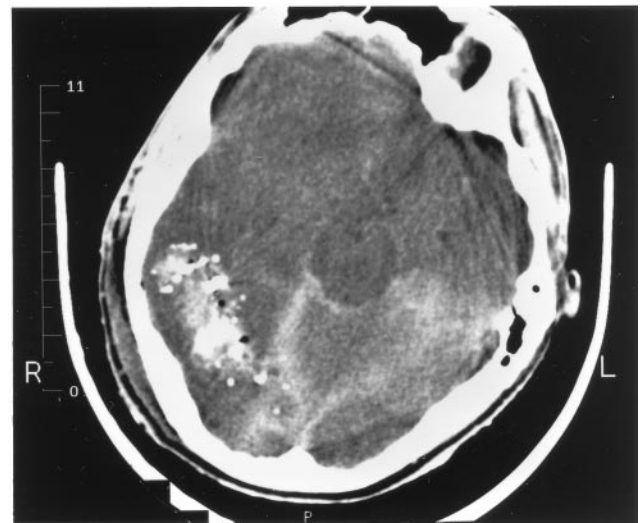
Haddad [6] summarized his experience and that of others at the conclusion of his article by making the following statements:

1. TICAs often remain undiagnosed.
2. Because of their involvement in more violent activities, men are more frequently affected than women. Peak incidence in the second decade is also a consequence of age related activities.
3. TICAs may appear as early as 2 hours postinjury. They may also appear in a delayed fashion (refer to Case 4).
4. Twenty percent of TICAs are multiple, and latency periods for appearance vary. This finding makes it imperative to consider studying patients at intervals in an attempt to identify TICAs that develop in a delayed fashion (refer to Case 4).



13 Left internal carotid artery arteriogram demonstrating crossfill from right to left following right internal carotid artery coil vessel sacrifice and left internal carotid angioplasty for vasospasm.

5. TICAs may regress, resolve, or grow with time (refer to Case 1 and 2).
6. TICAs appear most frequently on peripheral branches of the middle cerebral artery and less often on the pericallosal artery. Occurrences are rare in the posterior circulation (refer to Case 1).
7. Bullets tend to completely transect vessels, whereas lower-velocity shrapnel fragments tend to injure the vessel wall without disrupting its continuity. The latter are more likely to lead to TICA development.
8. TICAs are usually located in the distal part of a missile's trajectory.
9. TICAs are associated with intracranial hemorrhage in 80% of cases and subdural hematomas in 26% of cases (refer to Cases 1 and 2).
10. The wall of a TICA has minimal cellular elements and may frequently be a false aneurysm.
11. Angiographic spasm is rare in such cases (refer to Cases 2 and 4).

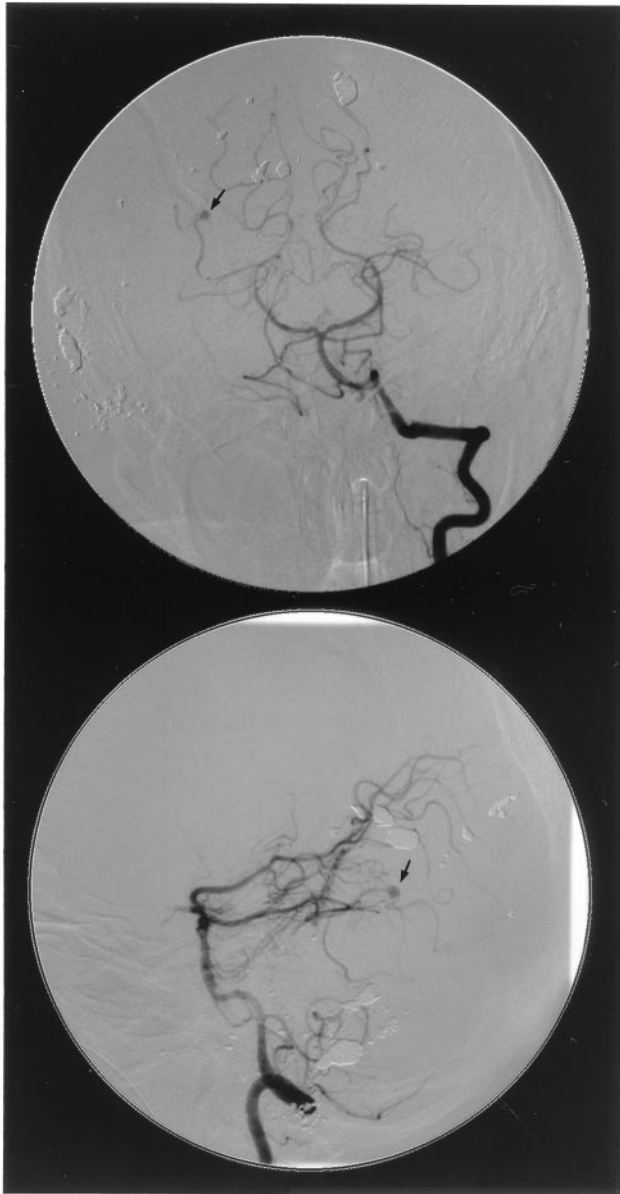


14 Head CT demonstrating a right temporo-occipital intraparenchymal hematoma and subarachnoid hemorrhage.

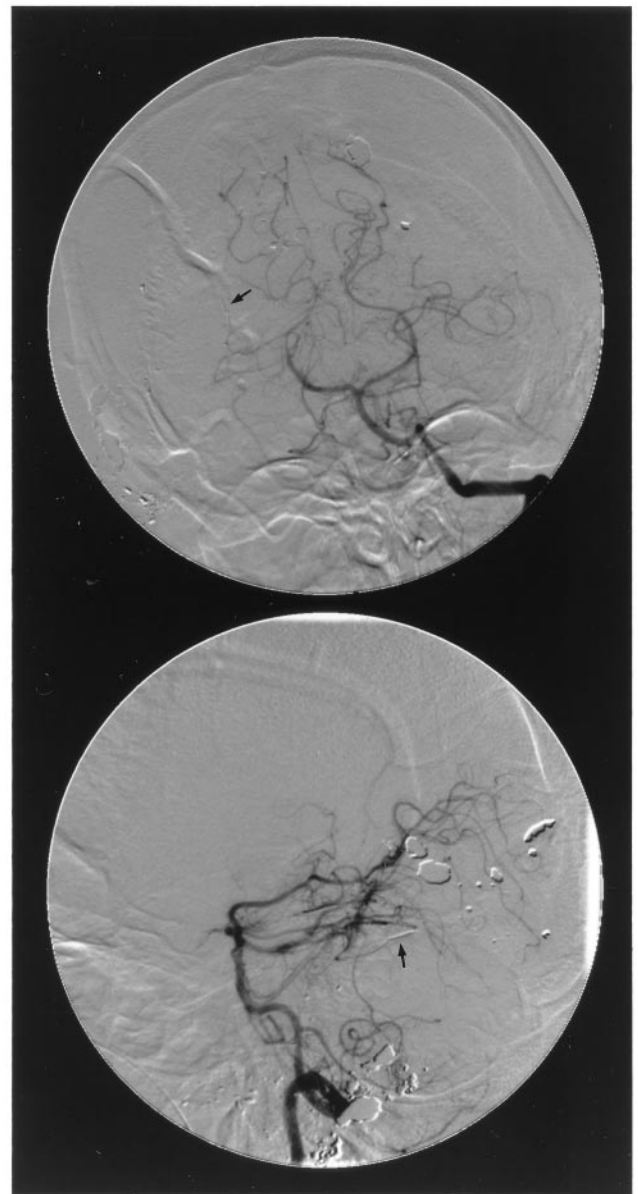
12. Whenever possible, TICAs should be trapped and excised.

Various treatment options were entertained for our five patients. These included proximal sacrifice of the afferent vessel, open surgical or endovascular trapping of the involved segment, primary clip reconstruction of the aneurysmal segment, aneurysm resection with interposition grafting using a segment of superficial temporal artery, and external carotid artery-MCA bypass using superficial temporal artery or saphenous vein.

In Case 1, vessel sacrifice either endovascularly with proximal coils, or surgically with proximal and distal trapping, was not considered ideal therapy for this particular case. While Peerless and Drake [12] have noted that the PCA has the richest potential for collateralization of all major cerebral vessels and found no persistent visual field deficits in 27 patients undergoing PCA occlusion, we did not want to place the occipital cortex at risk in a patient who already had visual loss from enucleation of the contralateral eye. Although clip reconstruction was a possibility, we were skeptical that we would be able to eliminate the aneurysm and its accompanying proximal and distal diseased segment of vessel while preserving a patent PCA lumen. The long-term effectiveness of such primary reconstruction was also doubtful, especially knowing that previous histologic studies have demonstrated significant weakness in the involved vessel wall at the site of injury. Any primary clip reconstruction would put the patient at risk for delayed aneurysm regrowth and rupture. The best option seemed to be aneurysm resection with interposition grafting.



15 Left vertebral artery arteriogram demonstrating a small right parieto-occipital artery aneurysm.



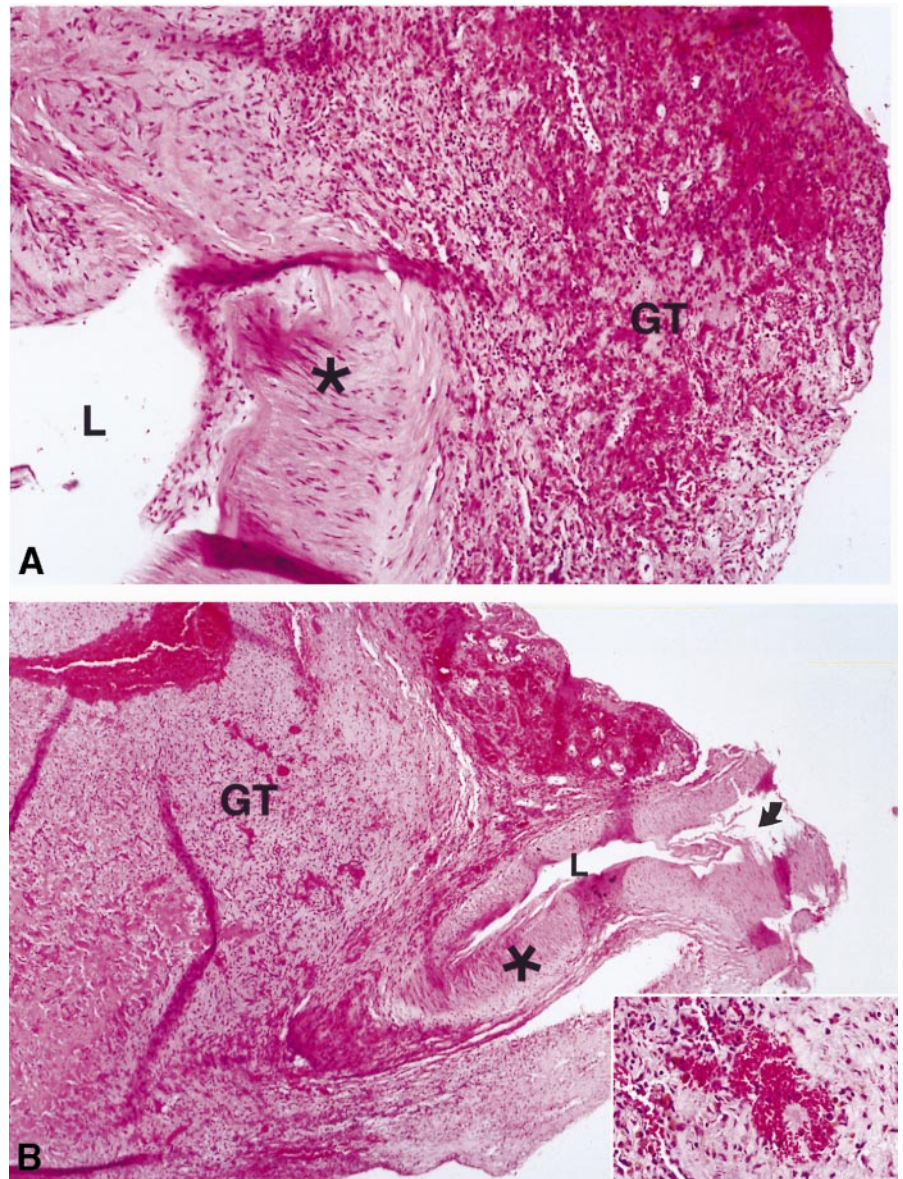
16 Right vertebral artery arteriogram demonstrating distal vessel sacrifice proximal to the aneurysm using platinum coils (arrow).

We were fortunate that aneurysm resection and interposition grafting was successful in this patient. The rich collateral flow to the occipital cortex no doubt provided protection from ischemic injury during the 60 minutes that it took to perform the two anastomoses. The additional benefits of patient cooling, general anesthesia, and etomidate burst suppression are indeterminate. Whether or not the patient would have developed a visual deficit with vessel sacrifice alone is unknown, and some might argue that tolerance to 60 minutes of occlusion is proof that interposition grafting was unnecessary.

Nevertheless, we are confident that successful grafting provided in both short- and long-term protection against potential collateral failure and infarction.

In Case 2, an initial STA-MCA bypass provided protection from the prolonged MCA occlusion time needed to clip reconstruct the aneurysm and would have permitted aneurysm trapping had this been necessary. In addition to demonstrating the benefit of the bypass procedure, this case along with Case 4 showed that vasospasm, although rare following subarachnoid hemorrhage from gunshots to

17 **A**, Higher magnification view shows myofibroblastic proliferation close to the area of disruption (**upper left**), scattered inflammatory cells, numerous hemosiderin-laden macrophages, and delicate blood vessels constituting granulation tissue. The lumen (L) is at the **lower left**, and the asterisk denotes the muscular wall ($\times 100$). **B**, Low-power view of traumatic aneurysm. The muscular layer of the vessel is indicated by an asterisk and the arrow shows the site of disruption. Fragmented remnants of the intima and a shaggy endothelial surface are seen on the luminal aspect (L). Abundant granulation tissue (GT) surrounds and partly buries the vessel wall. Fresh hemorrhage and numerous hemosiderin-laden macrophages (**insert**) are also seen ($\times 40$).



the head, is not impossible. It also illustrated the fact that not all TICAs develop along distal aspects of vessels.

In Case 3, the patient would not tolerate aneurysm trapping, as proven by immediate clinical failure during ICA temporary balloon occlusion. STA-MCA bypass followed by aneurysm trapping provided the best protection against fatal epistaxis. At the time this aneurysm was treated, GDC coils were not yet developed. Perhaps with the advent of this technology, this case could have been managed endovascularly.

In Case 4, open surgical trapping and STA-MCA bypass was considered; however, temporary balloon occlusion with EEG and SPECT information

provided us with the opportunity to treat the patient with simple trapping. By sacrificing the ICA proximally, using endovascular techniques, we provided protection against aneurysm rupture until definitive trapping could be carried out, provided early proximal control for subsequent surgery, and left the neck virgin so that a subsequent tracheostomy could be carried out without fear of contaminating a cervical incision.

In Case 5, proximal vessel sacrifice using endovascularly placed coils provided a quick and easy solution for obliteration of this distal aneurysm without putting the patient through the stress of a second craniotomy.

CONCLUSION

TICAs are rare finding. In order to detect them, surgeons must be suspicious whenever dealing with missile injuries to the head and investigate such patients with cerebral angiography. Our current management scheme includes both early and repeat angiography so that these dangerous lesions can be treated before they have the opportunity to rupture. While management can often simply involve Hunterian ligation or aneurysm trapping, arterial bypass or aneurysm resection with interposition grafting may be deemed necessary. As these five cases demonstrate, management uses multiple modalities with endovascular and surgical methods complimenting one another, so that the safest and most effective therapy can be carried out rapidly and efficiently.

REFERENCES

1. Aarabi B. Traumatic aneurysms of brain due to high velocity missile head wounds. *Neurosurgery* 1988;22:1056-63.
2. Acosta C, Williams PE Jr., Clark K. Traumatic aneurysms of the cerebral vessels. *J Neurosurg* 1972;36:531-6.
3. Bank WO, Nelson PB, Drayer BP. Traumatic aneurysms of the basilar artery. *AJR* 1978;130:975-7.
4. Courville CB. Traumatic aneurysm of an intracranial artery. Description of a lesion incident to a shotgun wound of the skull and brain. *Bull Neurol Soc* 1960;25:48-54.
5. Ferry DJ Jr, Kempe LG. False aneurysm secondary to penetration of the brain through orbitofacial wounds: report of two cases. *J Neurosurg* 1972;36:503-6.
6. Haddad FS, Haddad GF, Taha J. Traumatic intracranial aneurysms caused by missiles: their presentation and management. *Neurosurgery* 1991;28:1-7.
7. Hirsch JF, David M, Sachs M. Les aneurismes arteriels traumatiques intracraniaux. [Traumatic intracranial arterial aneurysms.] *Neurochirurgie* 1962;8:189-201.
8. Jackson FE, Augusta FA, Sazima HJ. Head injury and delayed epistaxis. Report of a case of rupture of traumatic aneurysm of internal carotid artery due to grenade fragment wound received in Vietnam conflict. *J Trauma* 1970;10:1158-67.
9. Kaufman HH, Sadhy VK, Clifton GL. Delayed intracerebral hematoma due to traumatic aneurysm caused by a shotgun wound: a problem in prophylaxis. *Neurosurgery* 1980;6:181-4.
10. Martin EM, Hummelgard AB. Traumatic aneurysms. *J Neurosci Nursing* 1986;18:89-93.
11. Moore D, Budde RB, Hunter CT. Massive epistaxis from aneurysm of the carotid artery. *Surg Neurol* 1979;11:115-7.
12. Peerless SJ, Drake CG. Surgical techniques of posterior cerebral aneurysms. In: Schmidek HH and Sweet WH, eds. *Operative Neurosurgical Techniques. Indications, Methods, and Results*. Ed 2. Philadelphia: WB Saunders, 1988;pp. 973-89.
13. Petty JM. Epistaxis from aneurysm of the internal carotid artery due to a gunshot wound: case report. *J Neurosurg* 1969;30:741-3.
14. Raimondi AJ, Yashom D, Reyer C. Intracranial false aneurysms. *Neurochirurgia (Stuttg)* 1960;11:219-33.
15. Robbins JR, Fitz-Hugh GS, Jane JA. Intracranial carotid catastrophies encountered by the otolaryngologist. *Laryngoscope* 1976;86:893-902.
16. Sadar ES, Jane JA, Lewis LW, Adelman LS. Traumatic aneurysms of the intracranial circulation. *Surg Gynecol Obstet* 1973;137:59-67.
17. Salar G, Minrino S. Traumatic intracranial internal carotid aneurysm due to gunshot wound: case report. *J Neurosurg* 1978;49:100-2.
18. Sarwar M, Barnitzski S, Schechter MM. Growing intracranial aneurysms. *Radiology* 1976;120:603-9.
19. Schmidt-Vanderheyden W, Backmund H. Angiographische Verlaufsbeachtung eines traumatischen intracerebralen aneurysmas. *Arch Psychiatr Nervenkr* 1971;214:10-6.
20. Spetzler RF, Owen MP. Extracranial-intracranial arterial bypass to a single branch of the middle cerebral artery in the management of a traumatic aneurysm. *Neurosurgery* 1979;4:334-7.

COMMENTARY

This is a very useful review of the topic of traumatic intracranial aneurysms secondary to missile wounds.

One of the important lessons from this paper is the value of bypass grafting in the management of these lesions. Surgeons such as myself, who used to routinely perform many EC-IC bypass procedures every year prior to the publication of the results of the EC-IC study, are finding it increasingly more difficult to bring ourselves to plan a bypass procedure. Because we are losing our technical competence in performing microvascular anastomosis, we try, if at all possible, to avoid bypass grafting. Also, because of this lack of technical proficiency, it takes us increasingly longer times to perform this procedure. Yet there is still an unquestionable role for bypass grafting in neurosurgery, and this article illustrates one of its undeniable indications. Traumatic aneurysms in general cannot be clipped; the parent vessel must be sacrificed, and they frequently occur in an artery that simply cannot be sacrificed without providing for distal perfusion in one way or another, usually by bypass grafting.

One point that this manuscript does not settle is the urgency with which a traumatic aneurysm must be occluded. Within the last 3 years, I have operated on two patients with traumatic intracranial aneurysms produced by a bullet (or in the most recent case, by a shotgun pellet) to the head. In both instances, the patient was being "observed" because of the increased intracranial pressure related to the initial wound. Marked enlargement of the aneurysm was demonstrated after the second

hemorrhage. Without scientific support, based on these two cases and anecdotal experience from the literature and from conversations with my colleagues, I am developing the concept that these aneurysms ought to be dealt with as soon as they are diagnosed, rather than waiting to see what happens on a repeat arteriogram.

Sometimes all that one finds, as in a couple of the cases in this paper, is a slight irregularity in one of the intracranial arteries. Frequently, as in one of our cases, the clue is a disproportionate amount of subarachnoid blood. Another clue is a large hematoma adjacent to a major intracranial vessel. When all that the initial angiogram shows is a very slight irregularity of the vessel, there is a temptation to wait a week or two and repeat the arteriogram to

see what has happened. How many patients rebleed in the interval? Certainly, my two cases and several others I am familiar with from the literature or from unreported anecdotes suggest that rebleeding frequently occurs within the first few days after the development of a traumatic aneurysm. I would suggest that, whenever possible, these aneurysms should be dealt with acutely. Fortunately, at least in some cases, interventional endovascular techniques, for which even a markedly increased ICP is not a contraindication, can be used.

Roberto C. Heros, M.D.

*Department of Neurological Surgery
University of Miami
Miami, Florida*

Plenty of evidence for waiting lists exists in Canada, another government funded system. . . . For breast cancer the median waiting time between diagnosis and the postoperative radiotherapy was 61.4 days. The physician author of this study says that if he were put on the waiting list for larynx cancer treatment—median waiting time more than forty days—he would “panic like hell. And then I’d go to Buffalo. . . .” In general, according to specialists, in 81 percent of cases surgery waiting times are longer than is reasonable, and 45 percent of all patients are waiting in pain. More than half the specialists attribute the waits to shortages in capacity.

—REGINA HERZLINGER
“MARKET DRIVEN HEALTH CARE” (1997)